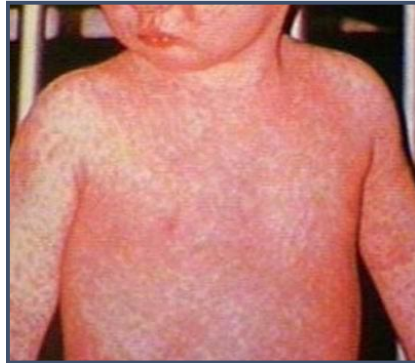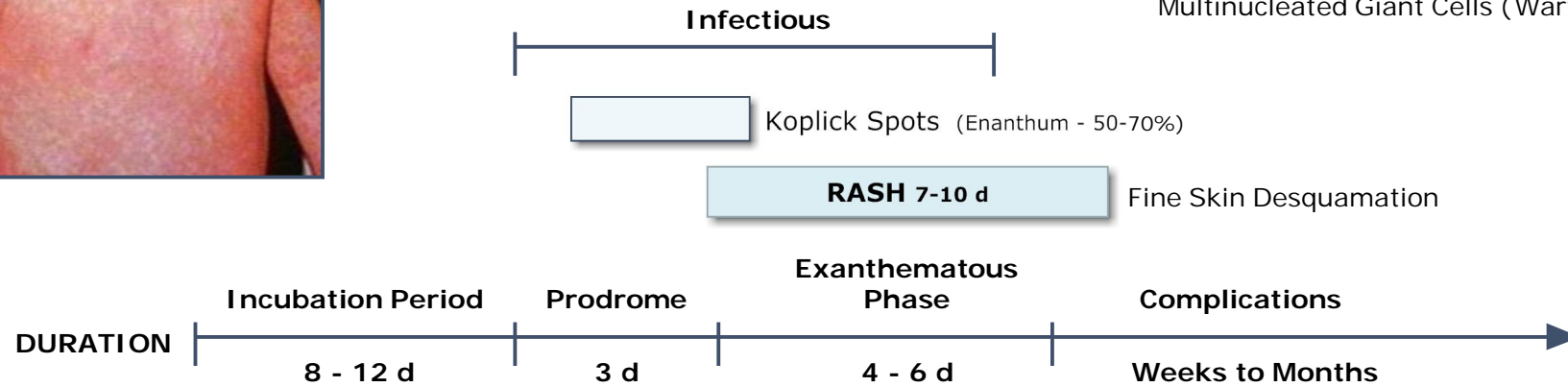


# MEASLES

Paul Tervit 2011



Single Stranded, lipid coated RNA virus  
 paramyxoviridae / morbillivirus  
 Necrosis of Respiratory Tract epithelium  
 Small vessel vasculitis  
 Synchitial Giant Cell Formation  
 Multinucleated Giant Cells (Warthin - Finkeldey )



## Differential Diagnosis

Rubella  
 Adenovirus  
 Enterovirus  
 Epstein-Barr Virus  
 Exanthum sibirum  
 Erythema infectosum  
 Mycoplasma pn.  
 Gp A strep  
 Kawasaki Disease  
 Drug Reaction

Fever  
 Cough  
 Conjunctivitis  
 Coryza  
 Photophobia  
  
 Giant Cell Formation

Pneumonia  
 Croup  
 Tracheitis  
 Bronchiolitis  
 Acute OM  
 Diarrhoea and Vomiting  
 Febrile Seizures  
 Encephalitis  
 Subacute sclerosis panencephalitis

Associated w Vitamin A deficiency

stat 200,000U age >1yr / or 100,000U 6m-12m  
 repeat the next day and at week 4.